

Case Report

An unusually large mucinous cyst of vulva

Burcu Kısa Karakaya^{1*}, Hatice Kansu-Çelik¹, Burak Ersak¹, Sebnem Ozyer¹, Mengü Turker², Ozlem Evliyaoglu¹

¹University of Health Sciences, Zekai Tahir Burak Women's Health Education and Research Hospital, Department of Gynecology, Ankara, Turkey

²University of Health Sciences, Zekai Tahir Burak Women's Health Education and Research Hospital, Department of Pathology, Ankara, Turkey

Abstract

Mucinous cysts are benign, are cystic lesions that can be encountered in vulvar region and filled with mucin. The majority of these cysts are small and asymptomatic. However, occasionally they may reach unusually large sizes, and may become pedunculated. Here, we report a case of vulvar mucinous cyst which was unusually large and pedunculated treated via complete excision.

Key Words:

Mucinous cyst, vulva, large, excision

Introduction

Mucinous cysts of vulva are benign, cystic lesions of the vulva which may involve mesonephric duct remnants, Bartholin glands, or the skene glands. They may also originate from the urogenital sinus remnants. They are submucosal in location, filled with mucin, and are lined by a single layer of a thin columnar mucinous epithelium [1]. Mucinous cysts usually occur in adults. They can be seen anywhere in the vulva, but most commonly confined to the vestibule. The majority of these cysts are small, asymptomatic, and are occasionally pedunculated. In this report, we

describe an unusually large, symptomatic and pedunculated vulvar lesion which was diagnosed as mucinous cyst.

Case Presentation

A 49-year-old multiparous woman was admitted to our outpatient gynecology clinic with the complaint of mass protruding from the left side of the vulva. A small, asymptomatic cystic lesion appeared soon after her last delivery about ten years ago, however, the cyst has become evident in size during the last 4-5 months and became painful. Her medical history was unremarkable. Pelvic examination revealed 3 and 6 cm smooth-surfaced cystic lesions originating from the left labium minus, attached with a thin, long peduncle. The mass was soft, easily compressible manually, and gave the impression of jelly-like material inside (Figure 1). The cyst was completely excised as the surgical treatment. The cyst contained mucopurulent material. Pathological examination

Article History:

Received: 20/06/2017

Accepted: 20/08/2017

*Correspondence: Burcu Kısa Karakaya

Address: Talatpasa Bulvari, Zekai Tahir Burak Women's Health Education and Research Hospital, Hamamonu, Altindag/ Ankara-TURKEY

Tel: +903123103100

e-mail: kisaburcu@gmail.com

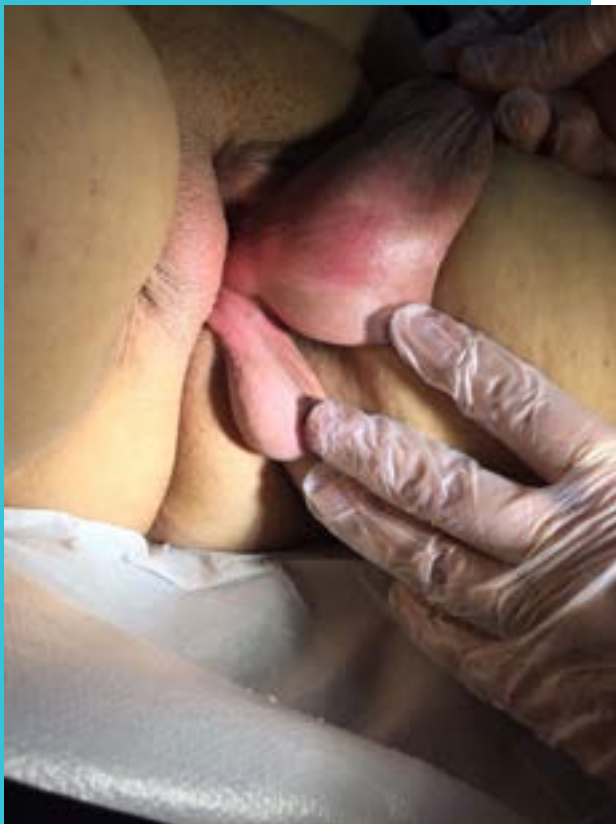confirmed the lesion to be a benign mucinous cyst (Figure 2). No complications were observed postoperatively. The patient was in good condition after 4-week follow up visit.

Discussion

A wide variety of lesions occur on the vulva. Vestibular mucinous cysts are solitary, benign, soft, smooth-surfaced masses which are domed and translucent filled with clear, viscous mucin located in the vulvar vestibule. There is limited data in the literature consisting of reports cases series [2]. There are different views about the embryogenesis of these cystic lesions.

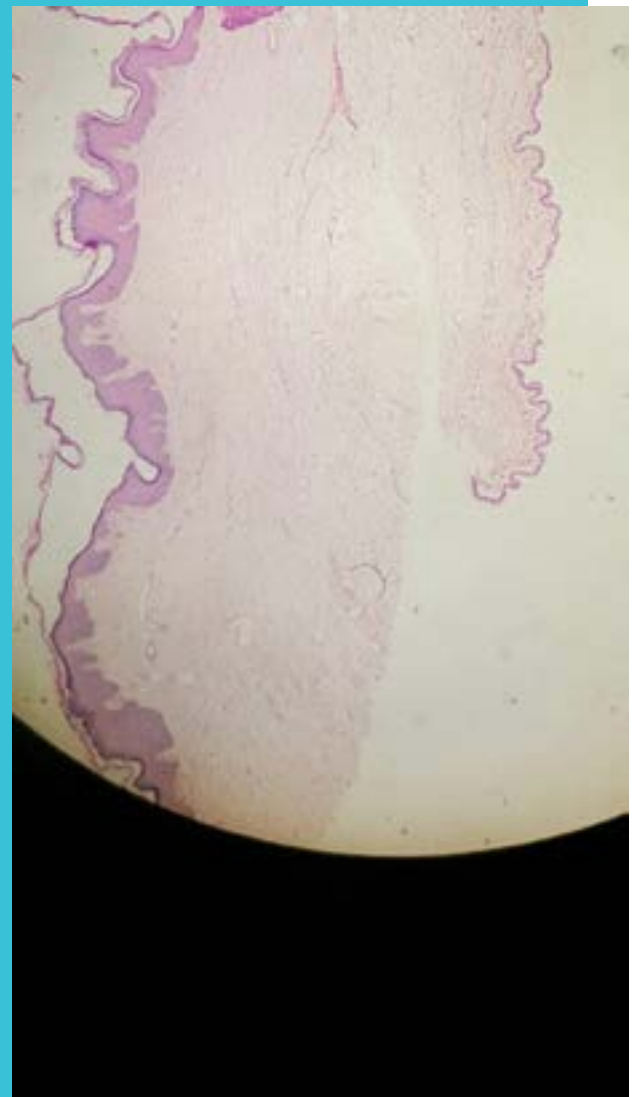
One of the first reports was by Friedrich and Wilkinson who presented 20 cases of mucinous cysts of the vulva, identified the clinical and pathological features. They suggested that these lesions are derived from the urogenital sinus endoderm, and with sexual maturity and hormonal stimulation, develop into cystic lesions [3].

Figure 1.



Macroscopic view of the vulvar cysts.

Figure 2.



Epithelial lining of the cyst consisting of mucin producing cells (H&E Staining)

Hart reported 3 cases, and indicated that the epithelial lining of these cysts is a simple layer of tall columnar cells with basally placed nuclei and cytoplasm containing abundant mucin. They suggested that because of this marked resemblance to the mucosa of uterine endocervix, these cysts are of paramesonephric (Müllerian) in origin [4]. However, Friedrich and Wilkinson commented that müllerian ducts does not contribute to the development of lower genital tract, and also epithelial lining of these cysts resemble those of the paraurethral and Bartholin gland systems derived from endodermal epithelium [3]. Because of the light and electron microscopic similarity of epithelial lining of vulvar vestibular mucinous cysts to the mucous secreting cells of the Bartholin and paraurethral gland systems, Oi and Munn suggested that these cysts are probably derived from urogenital sinus endoderm and are related to the development of the paraurethral, vestibular Bartholin gland system [5]. These lesions tend to be small and asymptomatic in most cas-

es, however, they are subject to trauma and may cause pain and discomfort when they grow larger. Larger masses may become pedunculated. In some cases, they may be infected resulting in abscess formation. Diagnosis is made clinically in most cases. Incision allows the jelly-like mucinous material to extrude which confirms the diagnosis (1) Symptomatic and/or large vulvar cysts are treated via excision. In conclusion, we report a case of vulvar mucinous cyst which was unusually large and pedunculated. They are benign masses which occasionally reach to large sizes and treated via complete excision.

Acknowledgement

None

Declaration of Interest

None

References

1. Oi RH, Munn R. Mucous cysts of the vulvar vestibule. *Hum Pathol.* 1982 Jun;13(6):584-6
2. UptoDate, Vulvar lesions: Differential diagnosis based on morphology. Authors: Lynette J Margesson, MD, FRCPC, FAAD, Hope K Haefner, MD. last updated: Dec 14, 2016.)
3. Friedrich EG Jr, Wilkinson EJ Mucous cysts of the vulvar vestibule. *Obstet Gynecol.* 1973 Sep;42(3):407-14
4. Hart WR. Paramesonephric mucinous cysts of the vulva. *Am J Obstet Gynecol.* 1970 Aug 1;107(7):1079-84
5. Oi RH, Munn R. Mucous cysts of the vulvar vestibule. *Hum Pathol.* 1982 Jun;13(6):584-6).